


Appendix F:

My Personal Experiences with Black Salve: Removing Skin Cancers & Keratosis Over 30 Years

Previously in this book, I wrote about my initial experience in removing a skin cancer with Cansema (Black Salve) in 1989.¹



The photo at right, taken on Sept., 3, 1989, is one of the few surviving photos from that period of my life. It was taken in Houston while vacationing with my first wife during the Labor Day weekend. Although in black-and-white and not detailed, the area under my left eye has completed the “heal over” process and any scar tissue is nearly imperceptible.

Although I subsequently used the Salve several more times in the years that followed to removed diseased tissue, it would be another 19 years before I used the Salve to eliminate growths that could have easily evolved into serious health threats.

It was the year 2008, and in connection with this event, I wrote about a series of five skin cancers I removed using Cansema (Black Salve).² I have no doubt that these growths came

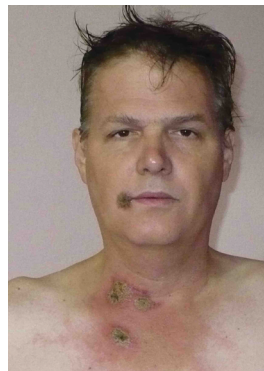
¹ This is discussed in Appendix A, “A Tear in the Matrix.” I also discuss this in my book, *Life on the Precipice* (2018), and the first draft of this material appears online at: www.meditopia.org/chap1.htm

² See: www.altcancer.net/docs/quack/eschar.htm. What I do here is expand on my experience, having had 10 years to further reflect. I also tie my own experiences into other elements of this book. So, yes, this is an expanded rewrite. The initial article about these Salve applications was integrated into an article I wrote condemning the disinformation about Black Salve that was being put out by the infamous QuackWatch website, as detailed earlier in this book. One other note of importance. We have consistently recommended that users of Black Salve apply to one area at a time. The reason behind this advisement is that there can be undo pain management issues if you apply to multiple areas at the same time. It is, as I’ve said repeatedly, akin to

about as a result of the tremendous stress I was under at the time. I had already noticed a definite correlation between stress events in my life and the subsequent arrival of malignancies. The initial growth I removed in 1989 had a sun-tanning bed as a contributing factor, but what I didn't mention in my previous drafts of Meditopia³ is that I was also under enormous financial pressure and was dealing with the enormous stress of my first corporate bankruptcy. Once again, we're confronting the undeniable mind-body connection that exists with many cancers, as discussed previously in this book.

Prior to the emergence of these growths, I learned that I could never return to the U.S. safely – for reasons I discuss at length in Meditopia.⁴ These reasons center largely around my work as an herbalist, mostly as a result of Black Salve itself. Moreover, I learned that even living on another continent, I would never see an end to my legal problems in the U.S. We're in the second half of 2019, and these conditions persist even to the present day.⁵

The next photograph was taken on May 27, 2008 by a friend from Guayaquil, Ecuador who is a medical doctor. At that time I was 52 years old, residing in exurbs outside of Guayaquil. I had just made a series of applications on growths, all of which were manifesting the same symptoms of skin cancer I had observed occasionally since that first application of



adding salt to your food. "You can always add more, but you can't take it out." I did not follow my own advise on this occasion, as I am better versed in pain management options than most.

Again, see: www.altcancer.net/cansema_pain.htm

³ See: www.meditopia.org/chap1.htm.

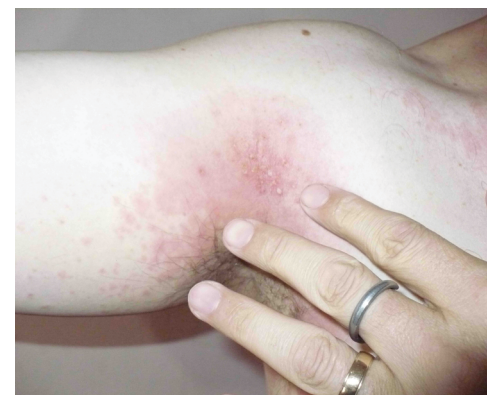⁴ Chapter Three begins at: www.meditopia.org/chap3-1.htm.

⁵ In fact, I was briefly held in detention in February, 2018 in Mexico City, in transit to a conference in Acapulco, where I was a scheduled speaker. Reason? The U.S. government refuses to remove my name and information from the Interpol Red List, even though this is a matter that was completely adjudicated by September, 2011. Sure, I can get my name removed, if I want. It's a legal procedure that would cost me about \$50,000 in legal fees in the States. In other words, I have to pay a large sum to correct the malfeasance of officials in the U.S. government. I simply refuse to do that. I refuse to continue to participate in a system that's designed to shake down ordinary citizens for things that are no fault of anyone but those in charge.

Black Salve in 1989.

The growths, or suspected growths, themselves were located under the right armpit, to the right of the lips, several were located in and around the sternal end of the right clavicle, and just behind the left scapula on my back. The photo above shows the areas that I treated in 2008 – all except the growth behind the scapula and my armpit.

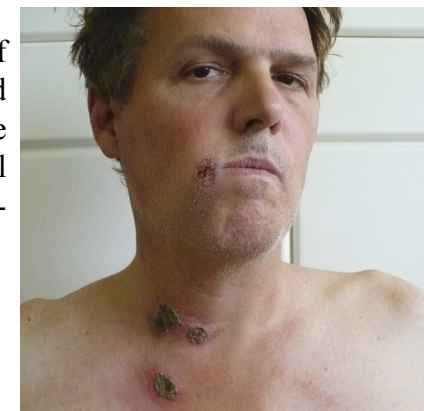Application Under Armpit: No Malignancy



The least eventful of this group was what I thought was a malignancy near my right armpit. I was wrong -- but this is the only suspected "growth" where I was wrong. Instead of an escharotic reaction, I saw the emergence of "pin-prick eschars," which

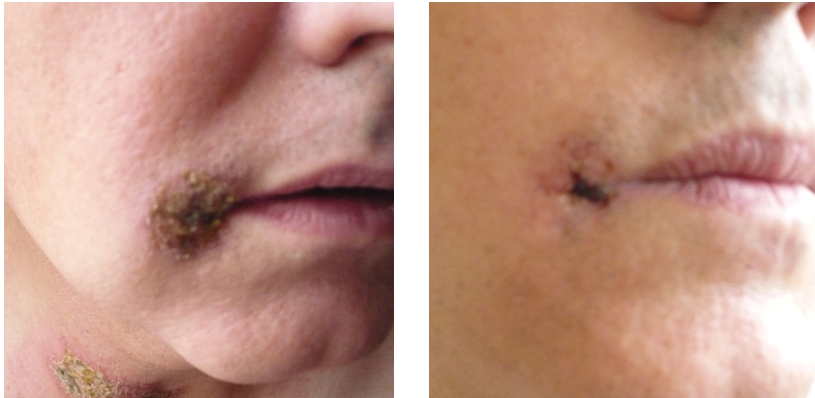
are not themselves demonstrative of an escharotic reaction. Instead, they usually indicate a high blood fungal count or a mild infection in the area, but these never arise, with no other escharization present, when applied to a malignancy. This NEVER happens.

The rest of the sites of application in the front all had reactions. I thought these were cancerous and I was right. I'll discuss the growth right lateral to the lips first.

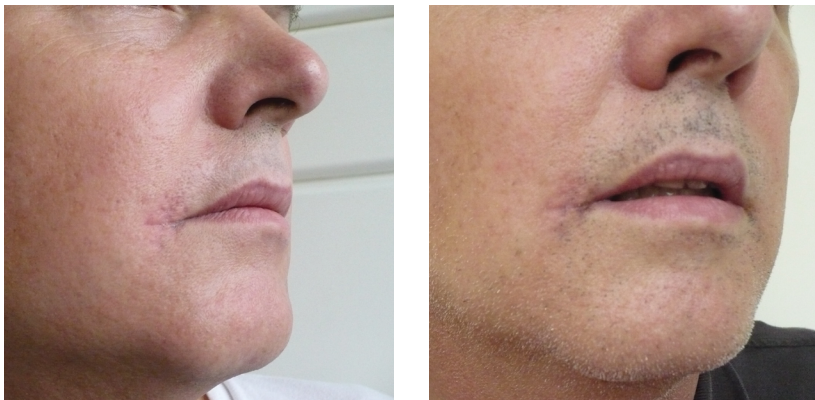

Lips: Right / Laberal -- malignant

The skin cancer at the right edge of my lips was particularly reactive, but not deep. I felt it working within seconds of application.



By June 3, 2008 – a couple weeks after the application – most of the eschar had already “flaked off,” leaving a small remaining eschar where the growth was the deepest, as you can see in the right photo above.

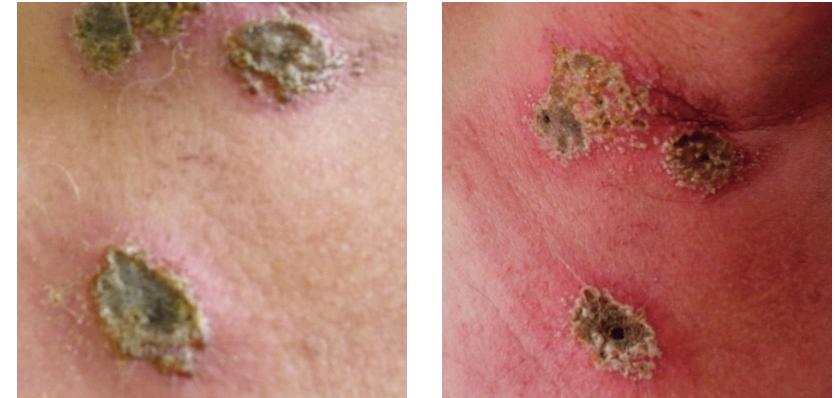


By June 12, 2008, the eschar had completely ejected, the decavitation filled in, and I was into “heal over.”

Nine days later (June 21) all that remained was minor hyperpigmentation that was gone in the subsequent weeks.

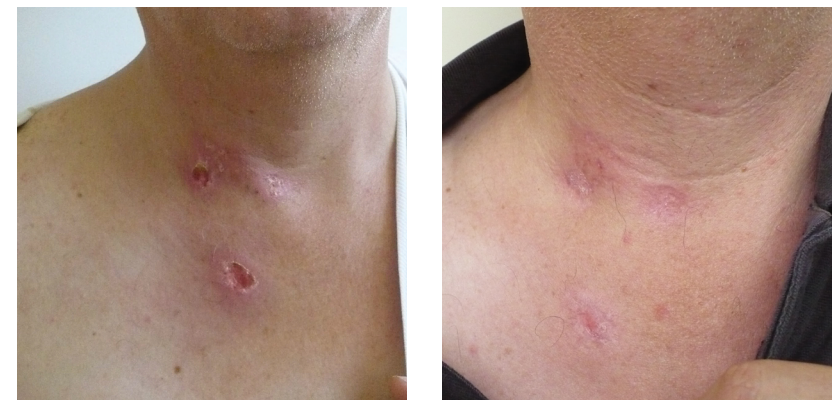Areas Around Right Clavicle

The application areas around the right clavicle turned out to be quite reactive, as well. The photos below – although not well-taken -- show the status of the applications made in early May.



Days later, these eschars began to “flake off” before the core came out in one piece, as seen in the photos above.

The left photo below, taken on June 7, show that a couple of the growths were relatively deep, given the size of the resulting decavitations.

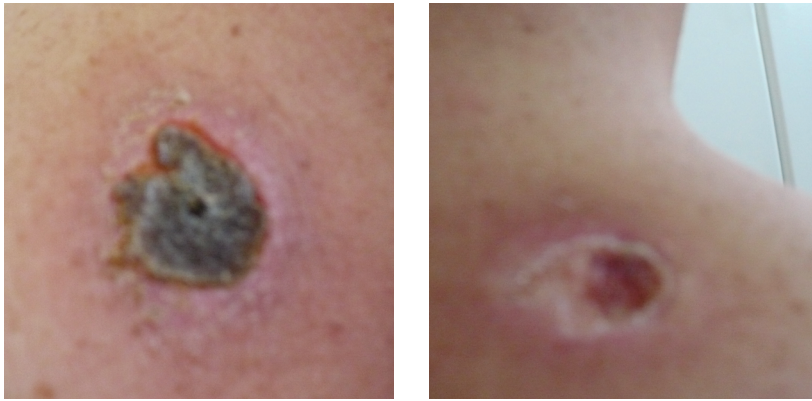


But by June 12, the decavitations had closed up cleanly.

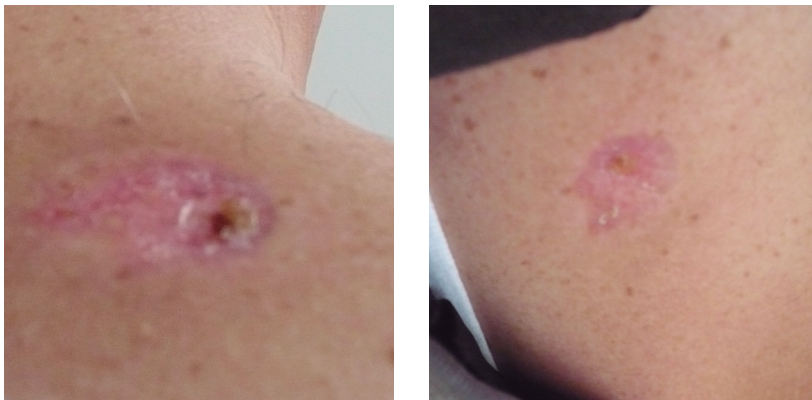By June 21, the process was clearly well into “heal over,” with only minor hyperpigmentation remaining.

Area Behind Right Scapula

The application on the back wasn't as reactive, but it developed into a sizeable growth about two inches in diameter. Speaking aesthetically, it was the most obnoxious looking. I didn't take a photo until May 30, by which time the eschar was already fully developed, and separation had begun in relation to the surrounding healthy tissue.



The right photo above was taken on June 7. This isn't a good photo, but you can still clearly see a wide, deep decavitation making its way to "heal over."



The left photo above was taken on June 12. By this time the decavitation had shrunk significantly in diameter and was nearly healed over. Next is an overhead shot of the same area, taken on June 21, 2008. At this stage, the area has nearly completely

healed over, with just hyperpigmentation remaining, which then resolved itself in the following months.

Ten Years Later: Diagnosed Actinic Keratosis

Sometime toward the end of July, 2017, I noticed a slight itch forming below my left lip. At first I thought it might have been in insect bite, because I travel in places in the forest where there are a lot of varied species of insects. In the months that followed the affected area grew to the point where there was not only a rash, but the itch got worse. I treated the area first with hydrogen peroxide and then with Lugol's Iodine.⁶

The iodine helped, but the growth never went ahead entirely. It always came back. For the first time since I acquired a skin disorder in my youth, I sought out professional help other than my own.⁷

A friend of mine in Cuenca, who's a dermatologist, agreed to examine me. The diagnosis was actinic keratosis.

Well, I know how to get rid of actinic keratosis.

Black Salve gets rid of actinic keratosis.

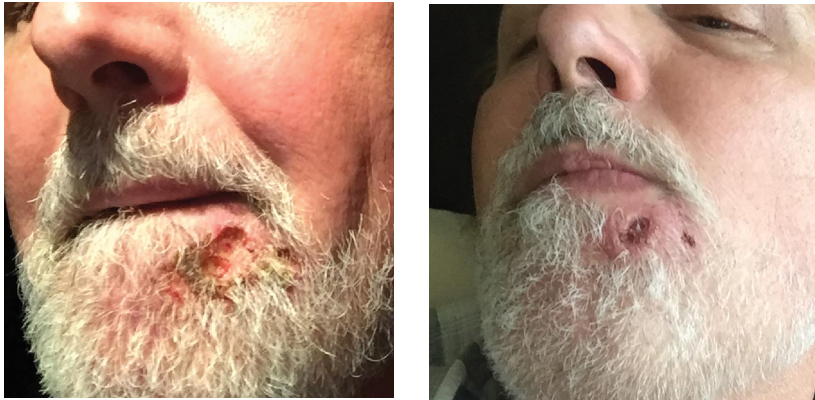I just didn't want to resort to something that aggressive if a gentler solution was available that was safe, effective, and without side effects. But such a solution didn't manifest. I know. I tried. So I began to apply Cansema.

The picture below was taken on November 6, 2017 after the first salve application. Escharization quickly occurred, followed by an ejection that left a small decavitation in one small part.

Later that very same day, more of the escharized areas reached decavitation.

⁶ We use both extensively in our work, although we do not sell hydrogen peroxide because suppliers abound. Articles on both can be found at: www.altcancer.net/h2o2.htm (for H2O2), and www.altcancer.net/lugols.htm (for Lugol's Iodine)

⁷ I suffered with Tinea versicolor, which I acquired in the Philippines in 1977, for several years. My dermatologists in the States consistently recommended a topical anti-fungal combined with Gris-PEG®, an antibiotic (not even an anti-fungal), which only relieved symptoms. See: www.rxlist.com/gris-peg-drug.htm. It didn't go away. Finally, I stopped taking pharmaceuticals entirely, focused on boosting my immune system, and eventually the problem went away entirely on its own. I haven't had a reoccurrence since sometime in the mid-80's.



By November 14 (2017), the decavitations were already well filled in and headed for “heal over.”

Two days later, the area was well into heal over:



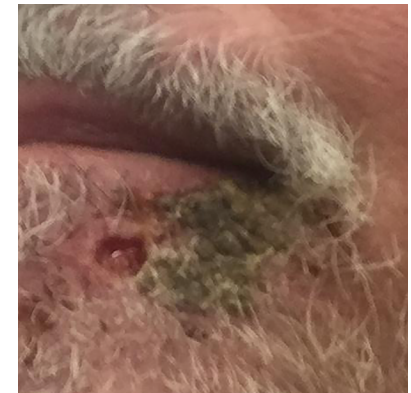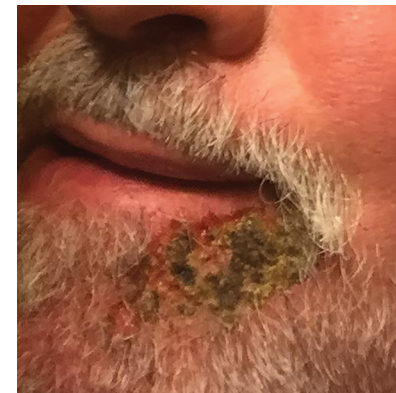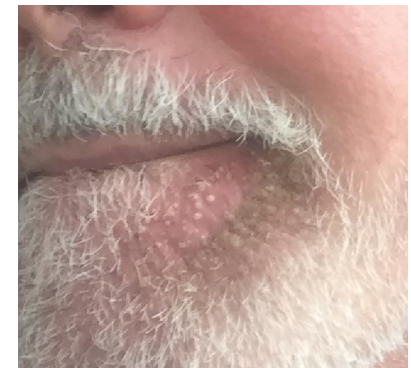At this point, I thought the job was finished. After a couple weeks even the hyperpigmentation was gone, and although a slight itch still remained, I was confident that this would resolve itself, as well. This was yet another misjudgment on my part, and therein lies a cautionary tale. Even those of us who know escharotics best can occasionally err. Despite working with untold thousands of cases, I have – even on my own body – “tested” a spot with Black Salve that I felt was a developing malignancy, only to get no reaction. I’ve had instances where I thought “one application will do it,” only to later realize that one or more fur-

ther applications would be required to rid myself of the diseased tissue. This was such a case.

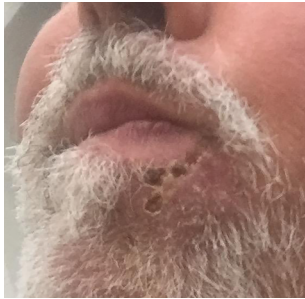Caught in the day-to-day minutia of daily business, book writing, product development, running a farm, etc. I didn’t pay attention to the area, but after a few months I noticed that the itch was again intensifying. By the fall of 2018 I had had enough. “I’m gonna nuke this thing until it’s gone and there is no chance of recurrence,” I thought to myself.

By this time, one year had passed and I found myself at the end of November, 2018. The photo below was taken on November 27.

Not a lot can be seen in the general area in the next photo, except for a light rash and a few pimples. However, I knew the area was going to be very reactive, and it was. The left photo below was taken on December 4, about six days after yet another Black Salve application. By this time, the area was extensively escharized. A number of distinct, unconnected eschars had formed.



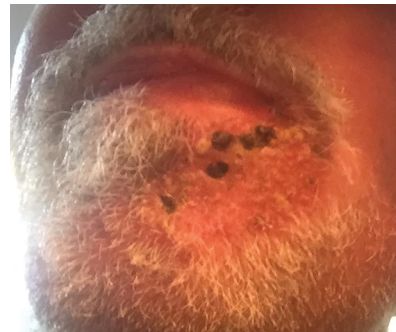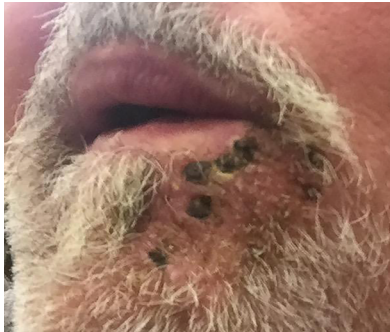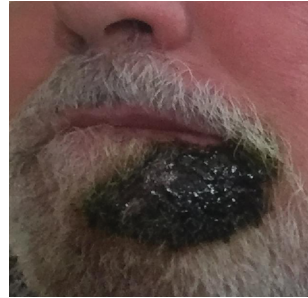By the next day, detritus from the eschars was already falling off, leaving, in one spot, a very prominent, circular decavitation.



By December 8, the eschars that formed had nearly all fallen off and the resulting decavitations were healing in fine.

Now I could have stopped at this point and just let the area heal over, since the Black Salve appears to have taken out all the diseased tissue. How-

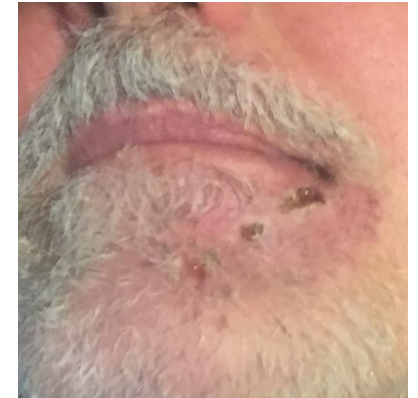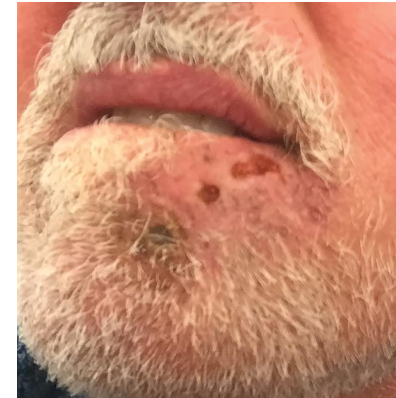ever, I did that a year earlier and you already know the result of that failed approach. So I “hit it” again as seen in the photo at right on December 9, 2018. This time, I didn’t just dab on the Salve. I covered the area thickly and broadly. I wasn’t about to take any chances. The reaction was immediate, however, the eschars that formed were smaller and deeper.



By the following day, December 10, I experienced serious edema -- for the first time treating this area. In fact, it affected the adjacent lip to the point where it distorted my entire face, as you see in the photos above. This told me that I was beginning to hit “pay dirt.” This also told me that the keratosis was more pervasive in the area than I had originally thought.

These eschars soon fell out.

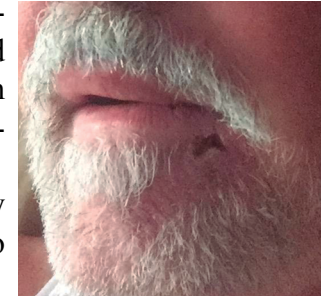By December 16, these decavitations were healing over nicely.



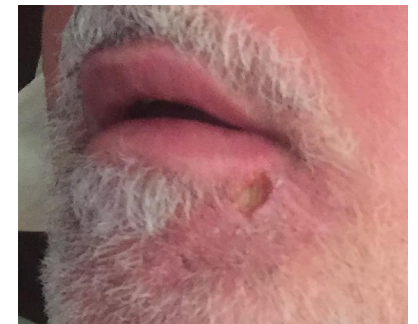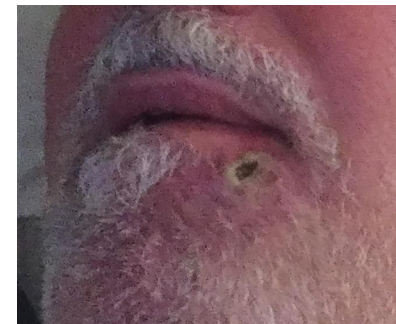
By December 23, very little remained.

Because I still felt a slight itch next to the corner of my mouth, I went and did a small application there. Another small eschar formed and came out. The photo at right, taken on January 22, 2019, shows the resulting decavitation:

At this point, I decided on January 6, to do one more broad application to ensure that I had “gotten it all.”



This time there was no reaction whatsoever, so was still left with the area near the edge of my mouth, since a new eschar had formed there.



Soon, this eschar fell out, leaving just the one remaining decavitation left to fill in. The right photo above was taken on January 31, 2019. The timeline on the removal of the growth in the area took longer because the uprooted diseased growth was

deeper.

Following the closing up of this decavitation, I felt no additional sensations in the area, as I had before. What I had to wait. By March 8, everything had healed over and very little hyperpigmentation remained. But I waited. By April 4, there were no changes. By the middle of June, still no changes:



As I write this, it is nearly September, 2019, and still there are no changes, so I feel confident that the applications I made at the end of 2018 have successfully cleared out the keratosis. The skin tissue in and around the area of application are clean and healthy. Gone are any of the telltale sensations that alerted me to a problem in the first place, and one recent application failed to produce any sensation or reaction.

When applying Black Salve to any diseased tissue capable of reacting escharotically, this is the end of the trail. This is the predictable end result of any properly applied Black Salve application.